



Effect of High-Power Laser on Shoulder Mobility in Sub Acromial Impingement Syndrome: Randomized Controlled Trial

Walid ahmed Kamal^{1*}, Mahmood Saber², Khalid Aiad³, Mohamed Serag Eldein Mahgoub Mostafa⁴, Heba A. Bahey El- Deen⁵

¹Physical Therapist MSC, ministry of interior, Egypt

²Professor of laser application in surgery National institute of laser Enhanced science, Cairo University, Giza, Egypt

³Professor of orthopedic physical Therapy, Cairo University, Giza, Egypt

⁴Associate professor Basic Sciences department -Faculty of Physical Therapy, Cairo University, Giza, Egypt

⁵Associate Professor of Physical Therapy, Department of Physical Therapy and Health Rehabilitation, College of Applied Medical Sciences, Jouf University, Kingdom of Saudi Arabia and Assistant Professor of Physical Therapy, Department of Physical Therapy for Surgery, Faculty of Physical Therapy, Misr University for Science and Technology, Egypt

Received: 06/05/2020

Accepted: 15/07/2020

Published: 20/09/2020

Abstract

The effect of high-power laser on shoulder mobility in subacromial impingement syndrome had been not investigated yet. Objective of study was to investigate the effect of high-power laser therapy on shoulder mobility in subacromial impingement syndrome. A Prospective, Randomized, pre - post- Test, controlled trial was conducted. Setting: Outpatient clinic of Cleopatra Hospital – Egypt. The Study was conducted between June 2017 and Feb 2018. Participants: Forty Patients who were diagnosed with 1 - 2 stage impingement syndrome pain was randomly divided into two equal groups. Interventions. Group (A) received a program of Neodymium- yttrium aluminum Garnet Laser 1064 nm wave Length Hiro 3 high intensity pulsed Laser was used in the study, Power of 8 W, dose of 12 J/cm² and Total maximum energy of 10000 J were Applied for 15 min and duration for single impulse 150 `us, fluency 760 mj, two sessions per week over six weeks' period in addition to exercise Group (B) Received Exercise in the form of Pendulum Ex. For 5 minutes, strengthen Ex for Anterior fiber of deltoid, stretching ex for sub scapularis muscle and anterior and posterior capsule. Main outcome measure: Visual Analogue Scale (VAS), active shoulder flexion and abduction, Ultrasonography of supraspinatus tendon thickness. Comparing both groups post-program revealed a statistically significant reduction in Ultrasonography Dimension of supraspinatus and VAS and significant increase in ROM of shoulder flexion and abduction in favor to group A in compared to group B (p > 0.05). It's concluded that high level laser Therapy was yielding more improvement for shoulder mobility in impingement syndrome.

Keywords: Impingement syndrome, High level Laser Therapy, Shoulder mobility

1 Introduction

subacromial impingement syndrome is characterized as an asymptomatic irritation of the rotator cuff and the subacromial bursa in the subacromial space [1] the term encompasses a wide range of disorders, causing an alteration in the relationship between the [inflammation] soft tissue and the [stiffness] structure, which is especially critical when the arm is removed in an arc between 60 degrees and 120 degrees [2]. Sub-acromial impingement syndrome (SIS) is characterized by extreme pain spreading across biceps and deltoid from the shoulder, pain rises at night, and with abduction and interned rotation [3]. Sub-acromial impingement syndrome is one of the most common causes of shoulder pain and occurs when the rotator cuff muscles are squeezed in the sub-acromial space and the acromial arch of curacao [4]. Numerous predisposing factors play a role in the development of SIS, with the most prominent risk factors being poor rotator cuff muscles, irregular scapular muscle function, articular capsule defects and long-term overhead arm movement, the muscle imbalances between upper and lower trapezius muscle activity are related to abnormal scapular motion in patients with shoulder pain [5].

SAIS induces edema, swelling, and can become chronic if appropriate treatment is not implemented, conservative and surgical treatment methods can be used to minimize discomfort, increase joint mobility, enhance muscle strength and quality of life in SAIS. Conservative treatment strategies include analgesic and non-steroidal anti-inflammatory or corticosteroid medications, resting, adjustment of routine triggers, approaches to physical activity, range of movement and strengthening exercises, local anesthetic subacromial injections [6]. Laser therapy is based on the belief that laser radiation and possible monochromatic light in general are capable of changing the function of the cell and tissue in a way that depends on the characteristics of the light itself, e.g., wavelength, coherence [7]. High-intensive laser therapy (HILT) involving high-intensity laser radiation causing minor and slow light absorption by chromium spheres, this absorption is not obtained with concentrated, light by diffuse light in all directions 'scattering phenomena, increasing mitochondrial oxidative reaction and adenosine triphosphate, RNA or DNA photochemical [8]. This study reported that high power laser improves shoulder mobility in subacromial impingement syndrome. Up to our knowledge there is no one use ultrasonography as objective method to assess this improvement and also use different type of

*Corresponding author: Walid ahmed Kamal, Physical Therapist MSC, ministry of interior, Egypt. Email: walidkamal558@gmail.com.

exercises. There is limited research studying the effect of high-power laser therapy on shoulder mobility in subacromial impingement syndrome. Did high power laser improve shoulder mobility in subacromial impingement syndrome?

2 Materials and methods

2.1 Study design

Study design the study was designed as a prospective, randomized - pre – post – test-controlled trial. The study was conducted between June 2017 and February 2018.

2.2 Participants

40 patients (20 males - 20 females), with SAIS was selected from outpatient's physical therapy department of Cleopatra hospital. The patients confirmed their agreement to participate in the study by signing an informed consent form. The inclusion criteria of this study included patients clinically and radiologically diagnosed as subacromial impingement syndrome with their ages ranged from 28 – 45 years old and complained from unilateral stage 1 - 2 subacromial impingement syndrome from one month or longer and had finding compatible with nerve compression on

physic examination [9]. Patients with a restricted passive range of motion in the shoulder, severe cervical spondylosis, radicular arm pain, inflammatory rheumatoid disorders, acromioclavicular or glenohumeral osteoarthritis, calcium deposition, diabetes mellitus, thyroid disease, ischemic heart disease, or a cardiac pacemaker, and those with previous history of neurological disorders were excluded. Patients who had received physical therapy and rehabilitation, who had been injected steroids within 6 months preceding the study, and those who underwent shoulder surgery, were also excluded. All patients were screened, and No one were excluded.

2.3 Randomization

Informed consent was obtained from each participant after explaining the nature purpose and benefits of the study, informing them of their right to refuse or withdraw at any time, and about the confidentiality of any obtained information, the patients were randomly assigned into Two groups " study group and control group " by a blinded and an independent research assistant who opened sealed envelopes that contained a computer generated randomization card.

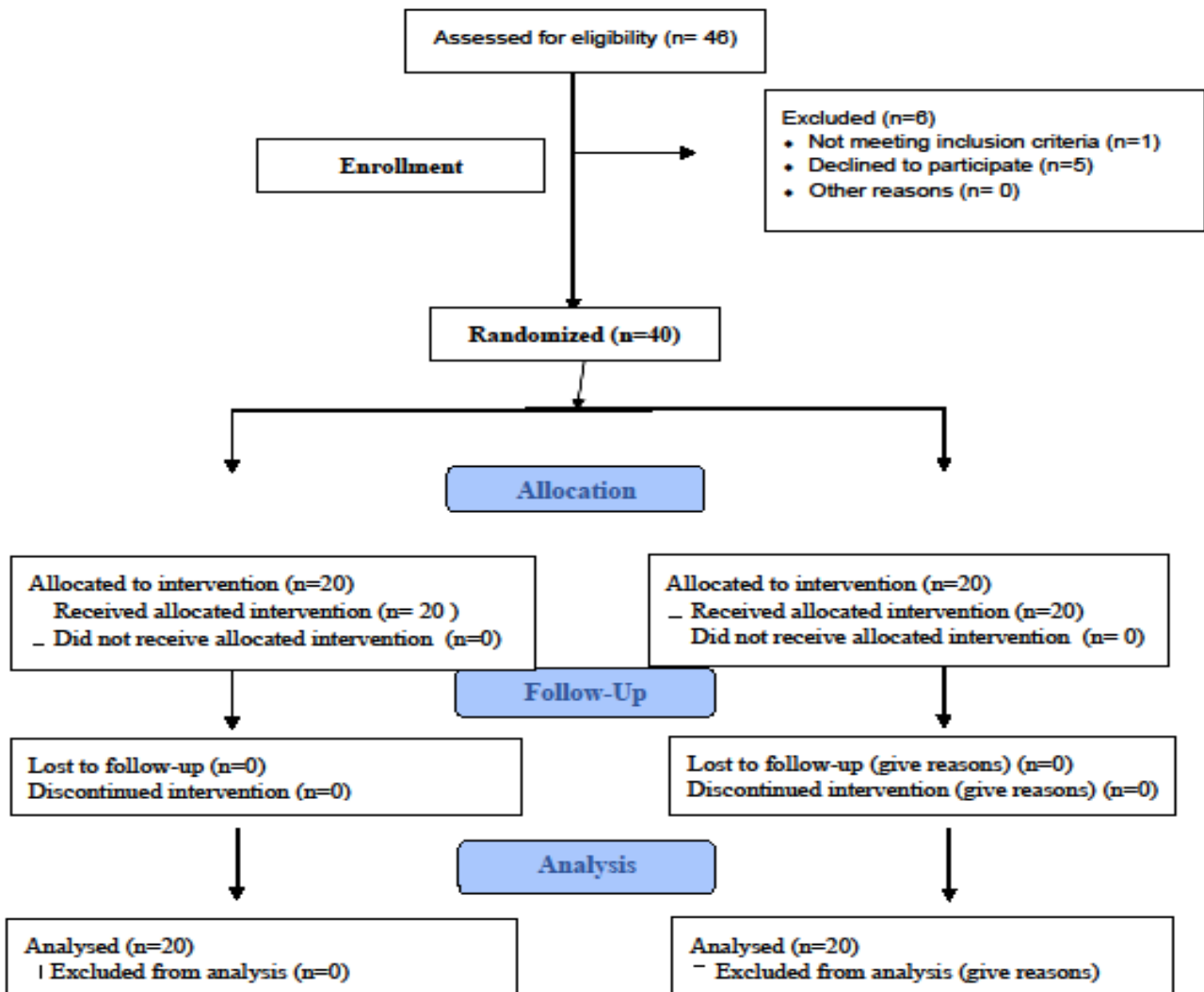


Fig 1: Flow chart of the participants.

No subjects dropped out of the study after Randomization

2.3 Interventions

The patients were randomly divided into two groups. Group (A): Composed of 20 patients. Who received 12 consecutive session of HILT Twice a weekly over 6 weeks in addition to therapeutic exercises. Group (B): composed of 20 patients who received therapeutic exercises alone. High intensity laser therapy treatment was done using (HIRO3.0 Nd: YAG pulsed laser) (Arcugnano, Via Volta, 9 Vicenza, Italy) peak power 3kW intensity 15000W/cm energy per pulse 350 mj.the treatment consisted of 3 phases in each session. the initial phase involved rapid manual scanning (100 cm²/30s) of the anterior joint line of the shoulder with one shot of 850 mj at frequency of 30 Hz. the scanning was performed parallel to the joint line, with the patient arm internally rotated on the posterior scan and externally rotated on the anterior scan the total energy dose administered during this phase was 4000J. the intermediate phase was a fixed scan phase , with one -shot emission of 350mj at a frequency of 20-25Hz.0.the total delivered energy was 4000J in this phase, the hand piece was applied vertically perpendicular to the shoulder joint for 5 sec.in each scan, the scanning included both the anterior and posterior joint line of the shoulder. The final phase involved rapid manual scanning of the same areas treated in the initial phase and the deltoid area until a total energy dose of 2000J.Application of all 3 stages of HILS took approximately 15 min. A stander hand piece equipped with affixed spacer was used to ensure the same distance to the skin. Both the subject and the operator wore protective goggles throughout the procedure to shield their eyes from laser. The patients were encouraged to exercise between sessions [10].

Each exercise session began with warm-up aerobic activities lasting for 10 to 15 minutes and ended with ice packs being applied on the affected areas for 5 minutes to relieve pain. The exercises were performed in 4 phases. Each patient, depending on his or her condition, started with phase 1 and progressed to phase 4. Phase 1 was aimed at achieving passive range of motion (ROM) without pain. For this purpose, the isometric shoulder exercise and the passive ROM exercise were performed in all directions 8 to 10 times per day. Postural exercises (eg, chin tuck and scapular retraction) and glenohumeral ROM exercises were also performed 15 to 20 times per day. In the event of a 50% increase in the ROM, the active-assistive ROM exercise was performed in all directions with the help of a strap. Also, in this phase cross-body and neck stretches were performed 4 times a day, each for a length of 10 seconds. Mobilization exercises were performed once per week. When a patient was able to perform the passive and active-assistive ROM exercises fully and painlessly, phase 2 (active ROM exercises) began. Shoulder abduction or scaption (scapular plane elevation) was performed by elevating the arm in the scapular plane to an angle of less than 60. Strength training was performed on the external and internal rotator cuff muscles while the arms were placed at the sides of the body. This exercise was in the form of 3 sets per day, each with 10 repetitions. The stretching exercises performed in phase 1 were also performed in phase 2, but their duration was increased to 15 to 20 seconds. The aim of phase 3 was to strengthen the muscles of the rotator cuff and scapula. Scaption was performed at an angle greater than 60. The exercises intended to strengthen the rotator cuff muscles responsible for external and internal rotation of the humerus were performed at a 90 angle to shoulder abduction. The reverse-fly, shoulder extension, and bent-over row exercises were performed using an elastic band or a 1- to 1.5-kg weight in 3 sets of 10 repetitions each. In phase 4, the exercises intended to train the scapular muscles were performed using a medicine ball. The exercises for strengthening the muscles of the rotator cuff and biceps were performed in 3 sets of 15 repetitions with a gradual increase of 25% to 50% in external resistance. Exercises were done

by 4 physical therapists from outpatient clinic of Cleopatra hospital for both groups [11].

2.4 Outcome Measures

All the assessment procedures were done before treatment and after finishing the treatment plan.

2.4.1 Visual Analogue scale (VAS)

Pain is assessed by using VAS which is a 10 cm calibrated line with zero representing no pain and 10 representing worst pain [12].

2.4.2 Active shoulder flexion and abduction

Electro goniometer was used to evaluate the mechanical condition of the joint by electronic components and is used today in research centers compared to radiography, the assessment of the Angle with the electrogoniometer shown high level of accuracy [13]. Active shoulder flexion and abduction were measured by the electrogoniometer device through a stander measuring procedure [14, 15].

2.5 Ultrasonography of supraspinatus tendon thickness

Ultrasonography was used as noninvasive examination with practically no side effects, it is beneficial in dynamic examination of the tendons during movement of the shoulder and assess the integrity of the rotator cuff tendons. If ultrasound is to reliably diagnose impingement, a dynamic assessment of shoulder abduction is required. The ultrasound test of impingement is performed with the arm abducted in or slightly forward of the scapular plane, as this facilitates simultaneous visualization of the relevant anatomical landmarks throughout the arc of elevation. The ultrasound literature reports an additional four dynamic signs of subacromial impingement: (a) "bunching" or fluid distension of the SA-SD bursa lateral to the impingement point at curacao-acromial arch [16] (b) "bunching" of the supraspinatus tendon lateral to the impingement point at curacao-acromial arch 5 , 6 ; (c) bulge of the curacao-acromial ligament 7 ; and (d) less commonly, complete "blocking" of supraspinatus tendon motion due to "migration of the humeral head upward to prevent its passage beneath the acromion.

Ultrasound examination was performed by a single radiologist with experience in musculoskeletal ultrasound scanning for more than 10 years. Both shoulders were evaluated in everyone. Acuson Sequoia 512 (Siemens, Germany) ultrasound scanner with an 8-15 MHz linear array probe was used. The axial spatial resolution for this probe was 0.280 mm. Ultrasonographic scanning was performed according to the protocol recommended by the European Society of Musculoskeletal Radiology, measurements of the thickness of supraspinatus tendon. The thickness of supraspinatus tendon was measured on the coronal view at the sulcus located between greater tuberosity and articular cartilage with the Modified Crass position. The Modified Crass position means placing the subjects' arm posteriorly and the palmar side of the hand on the superior aspect of the iliac wing with the elbow flexed, directed posteriorly. With this position, the probe was positioned more parallel to the supraspinatus tendon at the insertion site. The reason why we chose the Modified Crass position over the Crass position is that most patients with rotator cuff pathology experience less pain and are able to position closer to the instruction in the former than the latter. The probe was moved anteriorly and posteriorly to precisely observe the insertion of supraspinatus tendon located anteriorly to the running of the biceps tendon [17].

2.6 Statistical analysis

Results were expressed as mean \pm standard deviation (SD). A two-way mixed design MANOVA was run with two independent

variables – intervention and measuring periods– and four dependent variables (Ultrasonography of supraspinatus tendon thickness, VAS, ROM of shoulder flexion and abduction). There was a linear relationship between the dependent variables, as assessed by scatterplot, and no evidence of multicollinearity, as assessed by Pearson correlation ($|r| < 0.9$). There were no univariate outliers in the data, as assessed by inspection of a boxplot, and no multivariate outliers in the data, as assessed by Mahalanobis distance ($p > .001$). Ultrasonography Dimension of supraspinatus, VAS, ROM of shoulder flexion and abduction were normally distributed, as assessed by Shapiro-Wilk's test ($p > .05$). There was homogeneity of covariance matrices, as assessed by Box's M test ($p = .009$), and homogeneity of variances, as assessed by Levene's Test of Homogeneity of Variance ($p > .05$). Statistical Package for Social Sciences (SPSS) computer program (version 23 windows) was used for data analysis. P value ≤ 0.05 was considered significant and < 0.01 was considered highly significant.

3 Results

A total of 40 participants were eligible for inclusion, and were randomized for study intervention. Group A consisted of 20 participants who received 12 consecutive session of HILT twice a weekly over 6 weeks in addition to therapeutic exercises. Group B consisted of 20 participants who received therapeutic exercises alone three sessions per week for 6 weeks. All randomized participants completed the trial. The groups were similar at baseline ($p > 0.05$) with regard to age, height, weight and BMI (table 1). The interaction effect between type of intervention and measuring period on the combined dependent variables was statistically significant, $F = 452.606$, $p = 0.001$, Wilks' $\Lambda = 0.04$, partial $\eta^2 = 0.96$. There was statistically significant effect of intervention on the combined dependent variables, $F = 279.93$, $p = 0.001$, Wilks' $\Lambda = .063$, partial $\eta^2 = 0.937$. While, there was a statistically significant main effect of measuring periods on the combined dependent variables, $F = 1575.497$, $p = 0.001$, Wilks' $\Lambda = 0.012$, partial $\eta^2 = 0.988$. Multiple pairwise comparison tests (Post hoc tests) showed that the Ultrasonography of supraspinatus tendon thickness and VAS showed a significant reduction ($p < 0.05$) within both groups, while the ROM of shoulder flexion and abduction showed a significant increase ($p < 0.05$) within both groups. Comparing both groups post-program revealed a statistically significant reduction in Ultrasonography of supraspinatus tendon thickness and VAS and significant increase in ROM of shoulder flexion and abduction in favor to group A in compared to group B ($p > 0.05$) (Table 2).

4 Discussion

The current research was conducted to investigate the impact of high-level laser therapy in subacromial impingement syndrome on shoulder mobility. The mean value of VAS, electro goniometer, and Ultrasonography between groups prior to and after treatment was significantly different. The high intensity pulsed laser used in

this study can therefore suffice to decrease subacromial and sub deltoid bursitis This is the first study on the use of high intensity laser therapy in subacromial impingement syndrome and the use of ultrasonography as an objective method for assessment of subacromial and sub deltoid bursitis. A variety of causes, such as poor posture, weakness and deterioration of the rotator cuff and scapular muscles, decrease of ROM in the shoulder complex, degeneration and inflammation of tendons and bursa, acromial dysmorphology, capsular tightness and gleno-humeral instability are generally thought to lead rotator cuff disease [18]. The protocol used by karaka [19] and pekyvas [20] stipulated nine sessions on alternating days, three weeks, and Santa Mato et al. used 10 sessions " five sessions/week for two weeks," while our intervention protocol called for 12 laser sessions " two sessions/weeks for 6 weeks so our results come in agreement with Santa Mato et al who reported that high-intensity laser community had stronger improvements than ultrasonic [21].

Pakhavajs and Baltaci applied a placebo-free design and analyzed only the post-treatment outcomes, which showed that high-intensity laser therapy combined with other techniques of physiotherapy contributes to better results. This study is in line with other study published in 2015 by Sae Hoon et al. [10] who examined HILT's therapeutic effectiveness in patients with frozen shoulder [10]. 66 patients were divided randomly into two groups: HILT ($n=33$) and placebo laser ($n=33$). The HILT protocol required a therapeutic dose of 4000J for 15 minutes. Three weeks of treatment were given three times a week. VAS for pain, VAS for satisfaction and passive ROM were measured at baseline, after 3, 8 and 12 weeks of therapy. At baseline. Overall, the HILT group had three and eight weeks of clinically lower pain VAS ratings. Within 12 weeks, there was no significant difference in pain. Together, the HILT group had VAS scores of 3 and 8 weeks of clinically lower pain. There was no significant difference in pain within 12 weeks of this. No relevant effect or detectable harm was associated with the addition of high-intensity laser therapy to standard exercise therapy [10]. These findings are not in line with the findings of recent research work done by Javier et al [22] who stated that an intervention lasted for three weeks and comprised a total of 15 sessions (five sessions/week). During each session, participants received high-intensity laser therapy (experimental group) or sham-laser intervention (sham-controlled group); thereafter, all subjects received the same purpose-designed exercise therapy protocol for subacromial syndrome, consisting of stretching and strengthening exercises. They concluded that effect of high-intensity laser therapy plus exercise is not higher than exercise alone to reduce pain and improve functionality in patients with subacromial syndrome. [22]. The long-term effect of pulsed HILT in the treatment of post mastectomy pain syndrome was evaluated by Ebid and El-sodany [23] who reported that after 12 weeks of follow-up, HILT is an effective physical therapy modality for patients with PMPS. In fact, the HILT program is superior and has a more prolonged effect than a sham laser in pain reduction, increasing shoulder ROM, and improving and quality of life [23].

Table 1: General characteristics of subjects

	Study group(A) (n = 20)	Control group(B) (n = 20)	P value
Age (yrs.)	37.35 ±11.22	36.85 ±11.33	0.79 ^{NS}
Gender Male/ female	10 / 10	10 / 10	1.00 ^{NS}
Weight (Kg)	59.73 ±9.46	63.20 ±10.36	0.347 ^{NS}
Height (Cm)	157.80 ±10.80	165.80 ±11.70	0.415 ^{NS}
BMI (Kg/m ²)	19.48 ±4.41	20.54 ±2.72	0.532 ^{NS}

^{NS} P > 0.05 = non-significant, P = Probability. BMI: body mass index.

Table 2: Descriptive statistics and 2x2 mixed design Multivariate Analysis of Variance (MANOVA) for all dependent variables at different measuring periods at both groups

		Group A (n = 40)	Group B (n = 40)	P value*
Ultrasonography of supraspinatus tendon thickness	Pre-program	6.44 ±0.61	6.45 ± 0.62	0.98 ^{NS}
	Post-program	3.93 ± 0.31	5.16 ± 0.4	0.001 ^{HS}
	P value**	0.001 ^{HS}	0.001 ^{HS}	
VAS	Pre-program	6.74 ±0.59	6.51 ± 0.62	0.091 ^{NS}
	Post-program	1.51 ± 0.42	3.73 ± 0.66	0.001 ^{HS}
	P value**	0.001 ^{HS}	0.001 ^{HS}	
ROM of Shoulder Flexion	Pre-program	105.1 ±3.19	104.67 ± 3.4	0.567 ^{NS}
	Post-program	157.75 ± 4.56	121.17 ± 15.71	0.001 ^{HS}
	P value**	0.001 ^{HS}	0.001 ^{HS}	
ROM of Shoulder Abduction	Pre-program	105.1 ±3.19	105.1 ± 3.2	0.99 ^{NS}
	Post-program	152.45 ± 2.87	116.27 ± 3.74	0.001 ^{HS}
	P value**	0.001 ^{HS}	0.001 ^{HS}	

* Inter-group comparison; ** intra-group comparison of the results pre- and post-program.

^{NS} P > 0.05 = non-significant, ^{HS} P < 0.01 = highly significant, P = Probability, ROM: range of motion.

Kujawa J et al [24] reported that uses of a specific waveform with frequent peaks of elevated amplitude values and distances (in time) between them to minimize thermal accumulation phenomena and can quickly cause photochemical and photothermic effects in the deep tissue that increase blood flow, vascular permeability, and cease blood flow Vascular permeability, and cell metabolism [24]. HILT had an analgesic effect on nerve endings, but no evidence of decrease inflammation was found [25, 26]. Rotator cuff injuries are common issues although the individual affected may remain grossly asymptomatic until large muscle injury has already occurred. The incidence of partial-or full-thickness tears increases markedly after 50 years of age as rotator-cuff lesions are a natural correlation of ageing and are frequently present with no clinical signs [27]. In addition, HILT is the other recently experienced physiotherapy agent in clinical use. HILT effectiveness was compared with that of LILT in Bell's palsy treatment and HILT was found to be more effective. Its effectiveness was evaluated in two different studies on back pain compared to ultrasound; in one study it was found to be Effective pain and disability treatment; however, no difference was detected in the other study. [28, 29, 30] Furthermore, Kheshie AR et al [31] stated in their study that, HILT was found to be more effective than LILT in the treatment of knee osteoarthritis.

5 Conclusions

HILT was shown to be superior in short term effect for decreasing pain and improving mobility in patient with stage 1 and 2 SAIS, however, perhaps clinicians would be more willing to use HILT if the effectiveness of therapy were investigated, and favorable result obtained, in future studies outcome measure.

Ethical issue

Authors are aware of, and comply with, best practice in publication ethics specifically with regard to authorship (avoidance of guest authorship), dual submission, manipulation of figures, competing interests and compliance with policies on research ethics. Authors adhere to publication requirements that submitted work is original and has not been published elsewhere in any language.

Competing interests

The authors declare that there is no conflict of interest that would prejudice the impartiality of this scientific work.

Authors' contribution

We are three authors for this work, and we did all requirement to accomplish this work, there is no other researchers participate in this work.

References

1. De witted PB, NageLST, vanarkel ER, et al. study protocol subacromial impingement syndrome; The Identification of pathophysiologic mechanisms (SISTIM). BMC Musculo skeletal Disorder 2011; 12:282.
2. Leyes M and Forriol F. La rotura del manguito rotu-dor: etiologic. Exploration y tratamientc. trauma2012; 23 (suppl.1):39 - 56.
3. Santamato A, solfrizzi V, Panza F, et al: Randomized clinical trial people with subacromial impingement syndrome: versus ultrasound therapy in the treatment of short-term effects of high-intensity laser therapy. Phys Ther2009,89: 643-652. [Medline] [CrossRef].
4. Husni EM and Donohue JP. Painful Shoulder and Reflex Sympathetic Dystrophy Syndrome. Arthritis and Allied condition, 15th ed. Philadelphia: Lippincott Williams Wilkins, 2005, PP 2133-2151.
5. Abd Elhamed HB, Koura GM., Hamada HA., Mohamed YE, & Abbas R. Effect of strengthening lower trapezius muscle on scapular tipping in patients with diabetic frozen shoulder: A randomized controlled study. Biomedical Research, 2018: 29(3).
6. Dorrestijn O, Stevens M, Winters JC, van der Meer K & Diercks RL. Conservative or surgical treatment for subacromial impingement syndrome? A systematic review. Journal of shoulder and elbow surgery (2009). 18(4), 652-660.
7. Basfrd TR. low intending laser therapy. Still not an established clinical tool. laser sugar med 1995, 16-33-3-2
8. Zati A, Valente A. laser terrapin in medicine, terraria elision remove endodermic in medicine riabilitaire, Edizioni Minervamesica, 2006: 162 -185
9. Neer CS .2nd Impingement lesions. Clin Orthop Relat Res. 1983; (173):70-7.
10. Sae Hoon Kim, Yeon Ho Kim, Hwa-Ryeong Lee, Young Eun Choi. shor-term effects of high-intensity laser therapy on frozen shoulder: A prospective randomized control study, Manual therapy, volume 20, Issue 6 ,2015, Pages 751-757.

11. Parisa Nejati, Armita Ghahremaninia, Farrokh Naderi, Safoora Gharibzadeh and Ali Mazaherinezhad. Treatment of Subacromial Impingement Syndrome: Platelet-Rich Plasma or Exercise Therapy? A Randomized Controlled Trial. *The Orthopedic Journal of Sports Medicine* May 19, 2017.
12. Price DD, Bush FM, Long S, et al. A comparison of pain measurement characteristics of mechanical visual analogue and simple numerical rating scales. *Pain*. 1994; 56:217-226.
13. Norkin Cynthia C and D Joyce White. "Measurement of joint motion." *A guide to goniometry*. 2 (2003): 181-98
14. Goodwin J, mClark C, Deakes J, mBurdon D and Lawrence C. Clinical methods of goniometry a comparative study. *Disabil and Rehabil*. 1992, 14 (1): 10-15.
15. Norkin C and DJ White. *Joint Measurement. A Guide to Goniometry*. Philadelphia: FA Davis. 1985, pp: 56-93.
16. Farin PU, Jorama H, Harju A, Soimakallio S. Shoulder impingement syndrome: Sonographic evaluation. *Radiology*. 1990; 176: 845-8. [PubMed][Google Scholar]
17. Kyeongwon Kim, Hong Geum Kim, Daeheon Song, Jung Yoon Yoon, and Myung Eun Chung. Ultrasound Dimensions of the Rotator Cuff and Other Associated Structures in Korean Healthy Adults. *Korean Med Sci* 2016; 31: 1472-1478
18. Calis HT, Berberoglu N, Calis M. Are ultrasound, laser and exercise superior to each other in the treatment of subacromial impingement syndrome? A randomized clinical trial. *Eur J Phys Rehabil Med*, 2011, 47:375-380.
19. Karaca B. Effectiveness of high-intensity laser therapy in subacromial impingement syndrome. *Photo Med Laser Surg* 2016; 34(6):223-228.
20. Pekyavas NO and Baltaci G. Short-term effects of high intensity laser therapy, manual therapy, and Kinesio taping in patients with subacromial impingement syndrome. *Lasers Med Sci* 2016; (6): 1133-1141.
21. Santamato A, Solfrizzi V, Panza F, Tondi G, Frisardi V, Leggin BG & Fiore P. Short-term effects of high-intensity laser therapy versus ultrasound therapy in the treatment of people with subacromial impingement syndrome: a randomized clinical trial. *Physical Therapy*. July 2009, Volume 89, Issue 7, 1, Pages 643-652.
22. Javier Aceituno-go`mez, Juan Avenda`no-Coy, Julio Go`mez-Soriano. Efficacy of high-intensity laser therapy in subacromial impingement syndrome: a three-month follow-up controlled clinical trial. *Clinical Rehabilitation*. 2019, Vol.33(5):894-903.
23. Ebid AA and El-Sodany AM. Long-term effect of pulsed high-intensity laser therapy in the treatment of post-mastectomy pain syndrome: A double blind, placebo-control, randomized study. *Lasers Med Sci* 2015; 30:1747-1755.
24. Kujawa J, Zavodnik L, Zavodnik I, Buko V, Lapshyna A, & Bryszewska M. Effect of low-intensity (3.75-25 J/cm²) near-infrared (810 nm) laser radiation on red blood cell ATPase activities and membrane structure. *Journal of clinical laser medicine & surgery*, 2004; 22(2), 111-117.
25. Tsukya K, Kawatani M, Takeshige c, et al. Laser irradiation abates neuronal responses to nociceptive stimulation of rat-paw skin. *Brain Res Bull*. 1994; 34:369-374.
26. Nicolau RA, Martinez MS, Rigau J Tomas. Neurotransmitter release changes induced by low power 830 nm diode laser irradiation on neuromuscular junctions of the mouse. *Lasers Surg Med*. 2004; 35:236-241.
27. Milgrom M, Schafflery, Gilbert M, Van Holsbeeck. Rotator-cuff changes in asymptomatic adults: the effect of age, hand dominance and gender. *Journal of bone and Joint surgery*. 1995; 77(2):296-8.
28. Alayat MS, El-Sodany AM, El Fiky AA. Efficacy of high- and low-level laser therapy in the treatment of Bell's palsy: a randomized double-blind placebo-controlled trial. *Lasers Med Sci* 2014; 29:335-342.
29. Fiore P, Panza F, Cassatella G, Russo A, Frisardi V, Solfrizzi V & Santamato A. Short-term effects of high-intensity laser therapy versus ultrasound therapy in the treatment of low back pain: a randomized controlled trial. *Eur J Phys Rehabil Med*, 2011; 47(3), 367-73.
30. Boyraz I, Yildiz A, Koc B, Sarman H. Comparison of high intensity laser therapy and ultrasound treatment in the patients with lumbar discopathy. *Biomed Res Int*; 2015; 2015:304328.
31. Kheshie AR, Alayat MS, Ali MM. High-intensity versus low-level laser therapy in the treatment of patients with Knee osteoarthritis: a randomized controlled trial. *Lasers Med Sci* 2014; 29:1371-1376.