

MLS® Laser Therapy for the management of a non-healing venous leg ulcer: A Case Report.

Jill Pellizzon¹

¹ THE HILLS FOOT CLINIC - 227A Annangrove Rd, Annangrove NSW 2156, Australia

INTRODUCTION

Venous leg ulcers are chronic wounds that usually develop on the lower leg, particularly around the ankle, due to compromised blood circulation (Brem H. et al., 2004). They are the most common type of chronic leg injury, accounting for 70-90% of all lower limb ulcers (Snyder RJ., 2004). Venous insufficiency, a condition in which the veins in the legs fail to efficiently return blood to the heart, is the cause of these ulcers. Blood pooling in the lower legs can cause increased pressure in the veins and eventual damage to the surrounding tissues, resulting in ulcer formation. The prevalence of this condition increases with age, with 60% of patients developing their first ulcer after the age of 50. Women outnumber men about 2:1, but before the age of 40, men are more likely to be affected. Venous leg ulcers present as open sores on the lower leg, often accompanied by discolored, swollen, or hardened skin. Pain and fluid drainage may also occur. If left untreated, these ulcers can become chronic and result in complications such as infection and impaired mobility. Treatment for venous leg ulcers usually involves addressing the underlying venous insufficiency and promoting wound healing. Compression thera-

py, wound dressings, leg elevation, lifestyle changes (such as exercise and weight management), and, in some cases, surgery or other interventions may be necessary to repair or remove damaged veins.

At The Hills Foot Clinic, a podiatric center where I have been working for the last 25 years, we treat leg ulcers according to standard Australian guidelines (Sinha S., & Sreedharan S., 2014). We follow a standard protocol to improve wound healing in various conditions, which includes management with a general practitioner, debridement, medication, and dressing.

To improve patient care at The Hills Foot Clinic, we evaluated the use of laser therapy as an adjunctive treatment for the management of chronic venous ulcers.

The clinic was already using a laser with near-infrared wavelengths (808nm + 905nm). The Multiwave Locked System (MLS®) laser therapy was frequently used to rehabilitate patients with musculoskeletal problems such as osteoarthritis, Achilles tendonitis and plantar fasciitis.

Therefore, based on clinical evidence of the mechanism of action

of MLS® Laser Therapy (Micheli L. et al., 2019; Monici M. et al., 2013; Genah S. et al., 2021) and its proven analgesic, anti-inflammatory and tissue repair modulating effects, we decided to explore its integration into standard care for the treatment of chronic venous ulcers. The results of this evaluation were promising.

Presented below is a clinical case in which the MLS® laser treatment was used as an adjuvant treatment to improve wound healing in the management of a chronic venous leg ulcer.

MATERIALS AND METHODS

The MPhi 5 device (ASA Srl, Italy) was used to apply MLS® Laser Therapy, which is a class IV laser therapy system capable of emitting near-infrared (NIR) beams with wavelengths of 808 nm - 905 nm. The beams are spatially overlapped and synchronized, with continuous (or frequenced) and pulsed emission respectively. The system has an average power of 1.1W and a peak power of 25W.

The device has a multi-diode head that enables fixed or manual scanning of the anatomical area to be treated with homogenous energy delivery. The spot area is 19.6 cm². Additionally, the device is equipped with a handpiece for close-to-skin application with a spot area of 3.14 cm².

CASE REPORT

In August 2022, a 69-year-old woman with a history of varicose eczema, diabetes, and chronic psoriasis, along with dermatological and arthritic manifestations, visited The Hills Foot Clinic due to a chronic venous ulcer on her left medial lower leg.

The patient reported limited mobility and the need for a walker or cane to ambulate.

From November 2021, the ulcer was managed by a home nurse who changed the dressings once a week. However, it gradually worsened until February 2022 when the patient was hospitalized. Cultural tests revealed a *Pseudomonas aeruginosa* infection. The patient received intravenous antibiotic therapy and local antiseptic dressings. After a week, the patient was discharged, and bi-weekly dress changes and medication were prescribed.

Despite undergoing new treatment therapy, the patient's ulcer condition did not improve over the following six months. In fact, the pain worsened and became increasingly difficult to manage, necessitating the use of opioid oxycodone (Endone). This medication severely impacted the patient's daily life, as it interfered with her ability to sleep and concentrate.

In patient's words: "The home nurse came but the ulcers gradually got worse. I had to go to hospital. They put me on intravenous antibiotics. After seven days I returned home and then the wound clinic nurse came twice a week to dress them and treat them. They put heavy compression stockings on, and my ulcers got worse. I was crying with the pain and the frustration. I couldn't do anything. I've got animals. I would feed the animals, take the Endone, wait for it to kick in and then come inside and just put my legs up. I had no help. I'm on my own."

Standard therapy (debridement, medication, and dressing) was combined with MLS® laser treatment to reduce pain and promote healing.

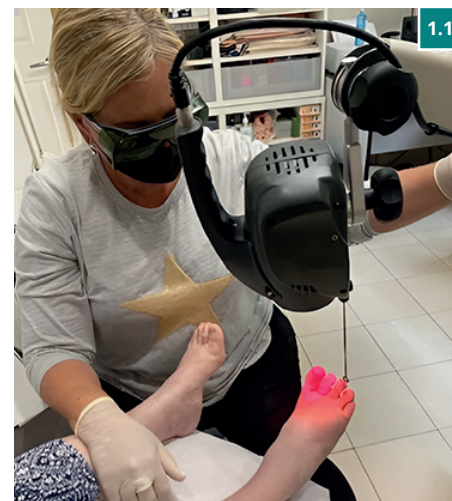The laser treatment was initially applied every other day, for the first 4 weeks. Due to visible signs of healing, the treatment was then reduced to once a week for a total of 10 treatment sessions over 48 days.

The multi diode head was used to apply laser treatment at approximately 20 cm from the skin (Figure 1). This was done after removing necrotic tissue and before administering medication and dressing. Both the patient and the doctor wore appropriate laser safety goggles.

During each session was treated the ulcer's area and the surround tissues. The device parameters were set as reported in Table 1.

During the initial treatment visit on August 18th, 2022, the ulcer presented an area of approximately 15 cm² (3 cm x 5 cm) - Figure 2.1. By the end of the visit, the patient reported a significant reduction in pain, which allowed her to discontinue the use of Endone. The analgesic effect was sustained throughout the treatment cycle, enabling the patient to cease taking opioids.

During treatment, the wound showed improvement with a progressive reduction in the superficial area, formation of granulation tissue, and reduction of exudate. The surrounding tissue inflammation also improved as the oedema gradually disappeared (see Figure



Figures 1.1
Example of the MPhi 5 multidiode head in action during a laser treatment session. The red light 635nm-68nm is used as a pointer, it has a maximum power of 1 mW and no therapeutic effects.

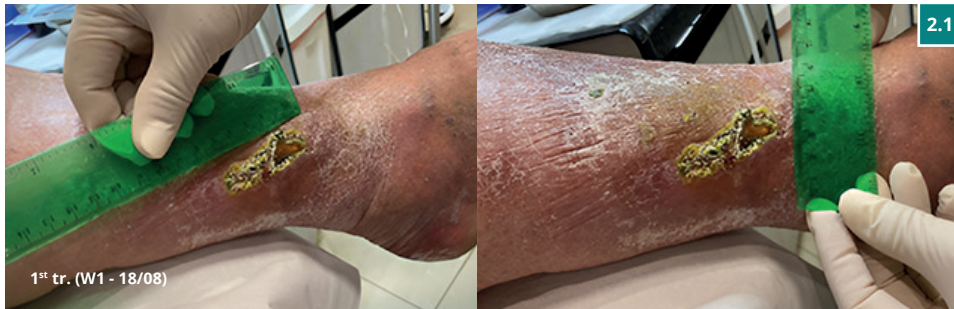2.2-2.6). By the fifth visit, the ulcer area had reduced by more than 50% (2cm x 1cm).

During the seventh visit, the patient reported a small trauma in the ulcer area, which appeared to have regressed. During a dressing change, green exudate was noticed. Due to discoloration at the edges of the ulcer, a recurrence of infection was suspected. The patient was sent to a general practitioner who prescribed a swab and preventive antibiotic treatment with Ciprofloxacin. After 5 days, the swab analysis showed no signs of infection, and the antibiotic therapy was stopped.

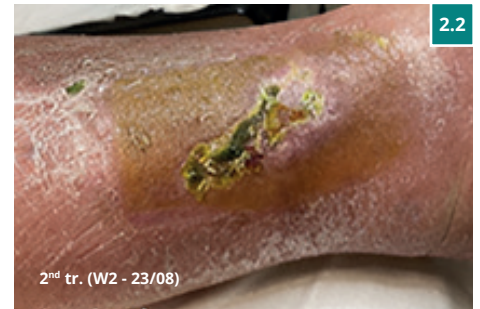At the 9th MLS® laser treatment, the remaining wound appeared significantly smaller, with a superficial area of approximately 0.45 cm² (0.9 cm x 0.5 cm) - Figure 2.9. After 48

| AREA (cm²) | FREQUENCY (Hz) | INTENSITY (%) | TOTAL ENERGY (J) | DOSAGE (J/cm²) | TIME (min:sec) |
|------------|----------------|---------------|------------------|----------------|----------------|
| 100 | 1500 | 100 | 798 | 7.98 | 08:00 |

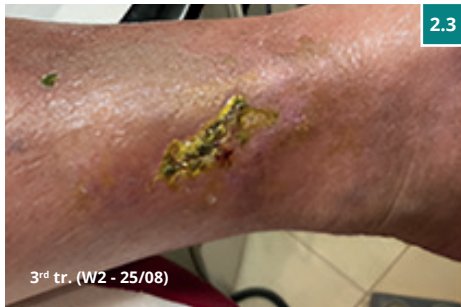Table 1
Setting used during each treatment session.



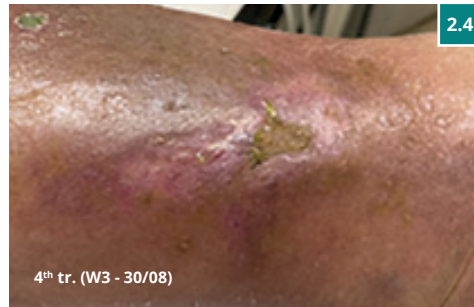Figures 2.1
Baseline visit, ulcer condition before debridement and first laser treatment.



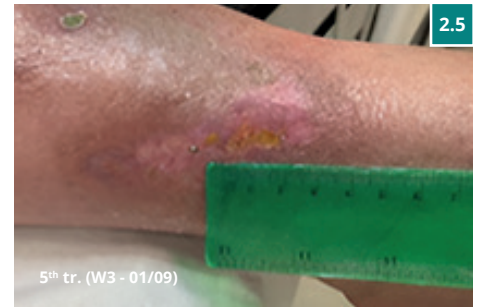Figures 2.2
Ulcer condition before removing necrotic tissue.



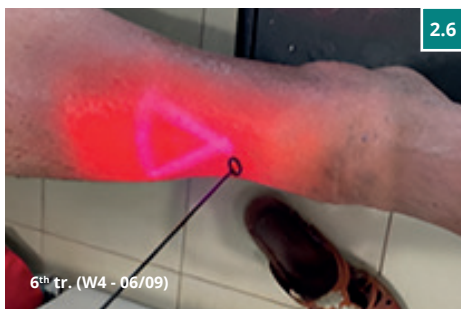
Figures 2.3
Ulcer condition after debridement and 3rd MLS® laser treatment.



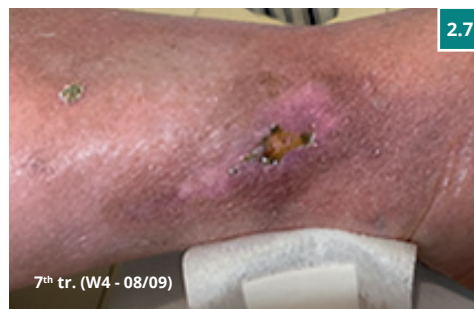Figures 2.4
The ulcer present depth reduced and eschar lifting with minimal scarring and surrounding skin much improved with significant reduction in leg's oedema.



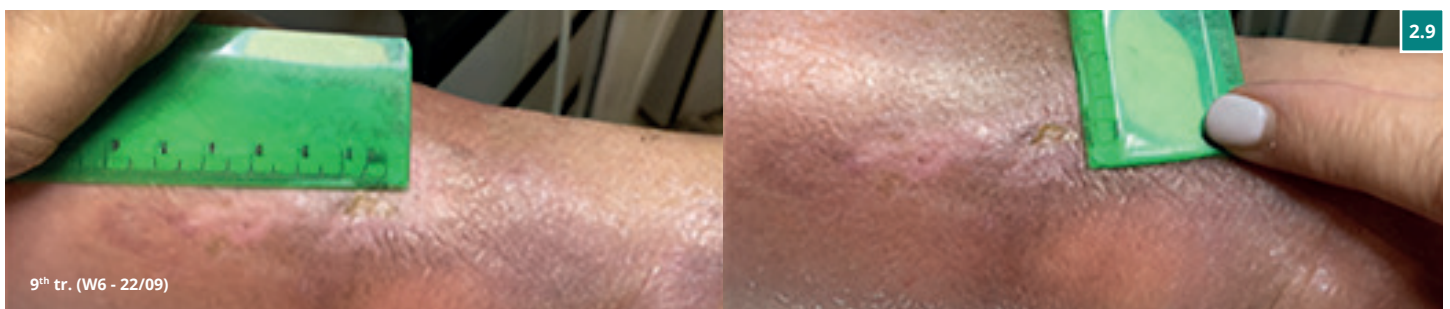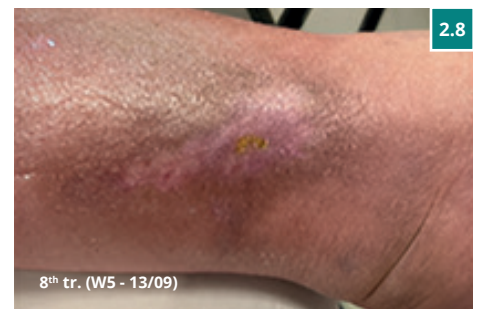Figures 2.5
In occasion of the 5th visit the ulcer appear with a granulating base, no exudate, and a superficial area of ~ 2cm².



Figures 2.6
Application of the MLS® laser during the 6th treatment, detain on the spacer used to maintain 20 cm distance from the skin.



Figures 2.7, 2.8
Ulcer regression due to a small trauma.



Figures 2.9
Ulcer condition after 5 weeks since the first treatment, superficial ulcer's area of 0.45cm².

days and 10 MLS® laser treatments, the ulcer had closed, the quality of the surrounding tissue improved and there was no oedema.

The patient was discharged with the only prescription to wear an elasticated tubular bandage for mild compression and protection of the fragile new skin.

No side effects were reported, and the satisfaction of the patient was high.

Patient said: "Look, for me, it was a miracle. I could not believe it. The ulcer is now totally fine. It is all clear. It was worth it. I'd do anything to get out of that pain. I could not stand it".

DISCUSSION AND CONCLUSION

Based on our clinical experience, the integration of laser therapy with traditional therapies is feasible and has been shown to promote and accelerate the healing process, particularly in chronic ulcers.

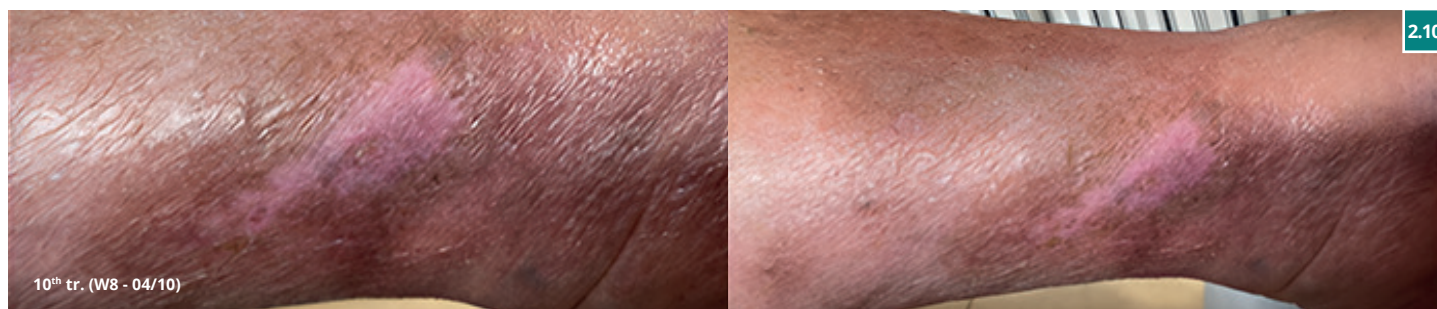These results are consistent with previous in-vitro studies and clinical cases involving similar problems, such as non-healing wounds and post-surgical ulcers in diabetes patients, always treated with MLS® Laser Therapy (Vignali T. et al., 2021; Tedeschi A. et al., 2023). This Case Report provides addi-

tional evidence on the potential restorative effects of MLS® Laser Therapy. However, randomized clinical trials are necessary to validate its application in treating chronic venous ulcers.

Note: all the photos reported have been given with patient's permission.

BIBLIOGRAPHY

1. H. Brem, RS. Kirsner; V. Falanga, Protocol for the successful treatment of venous ulcers., in Am J Surg, vol. 188, 1A Suppl, luglio 2004, pp. 1-8, DOI:10.1016/S0002-9610(03)00284-8, PMID 15223495.
2. RJ. Snyder, Treatment of non-healing ulcers with allografts., in Clin Dermatol, vol. 23, n. 4, pp. 388-95, DOI:10.1016/j.clindermatol.2004.07.020, PMID 16023934.
3. Sinha, S., & Sreedharan, S. (2014). Management of venous leg ulcers in general practice - a practical guideline. Australian family physician, 43(9), 594-598.
4. Micheli L., Cialdai F., Pacini A., Branca JJV., Morbidelli L., Ciccone V., Lucarini E., Ghelardini C., Monici M. & Di Cesare Mannelli L. Effect of NIR laser therapy by MLS®-MiS source against neuropathic pain in rats: in vivo and ex vivo analysis. Scientific Reports | (2019) 9:9297 | <https://doi.org/10.1038/s41598-019-45469-5>.
5. Monici, M., Cialdai, F., Ranaldi, F., Paoli, P., Boscaro, F., Moneti, G., & Caselli, A. (2013). Effect of IR laser on myoblasts: a proteomic study. Molecular bioSystems, 9(6), 1147-1161. <https://doi.org/10.1039/c2mb25398d>.
6. Genah S, Cialdai F, Ciccone V, Sereni E, Morbidelli L, Monici M. Effect of NIR Laser Therapy by MLS®-MiS Source on Fibroblast Activation by Inflammatory Cytokines in Relation to Wound Healing. Biomedicines 2021, 9:307. <https://doi.org/10.3390/biomedicines9030307>.
7. Viliani T, Lombardi B. Healing of Leg Diabetic ulcer treated with MLS®-MiS laser (MiS - MLS® High Peak Pulse): a case report. Medicina Fisica e Riabilitativa ASL Toscana Centro, Prato. Energy for Health [21] file:///E:/healing_diabetic_ulcer_with_mls_mis_laser.pdf
8. A. Tedeschi, C. Cosentino, E. Salutini, D. Fusilli, R. Anichini. Integrated new therapy to usual care in management of not healing wounds and post-surgical ulcers. Energy for Health [23] file:///E:/e4h23_new_therapy_not_healing_wounds_ulcers.pdf.



Figures 2.10

Last treatment, the ulcer seams completely closed, surrounding skin quality improved and no oedema.